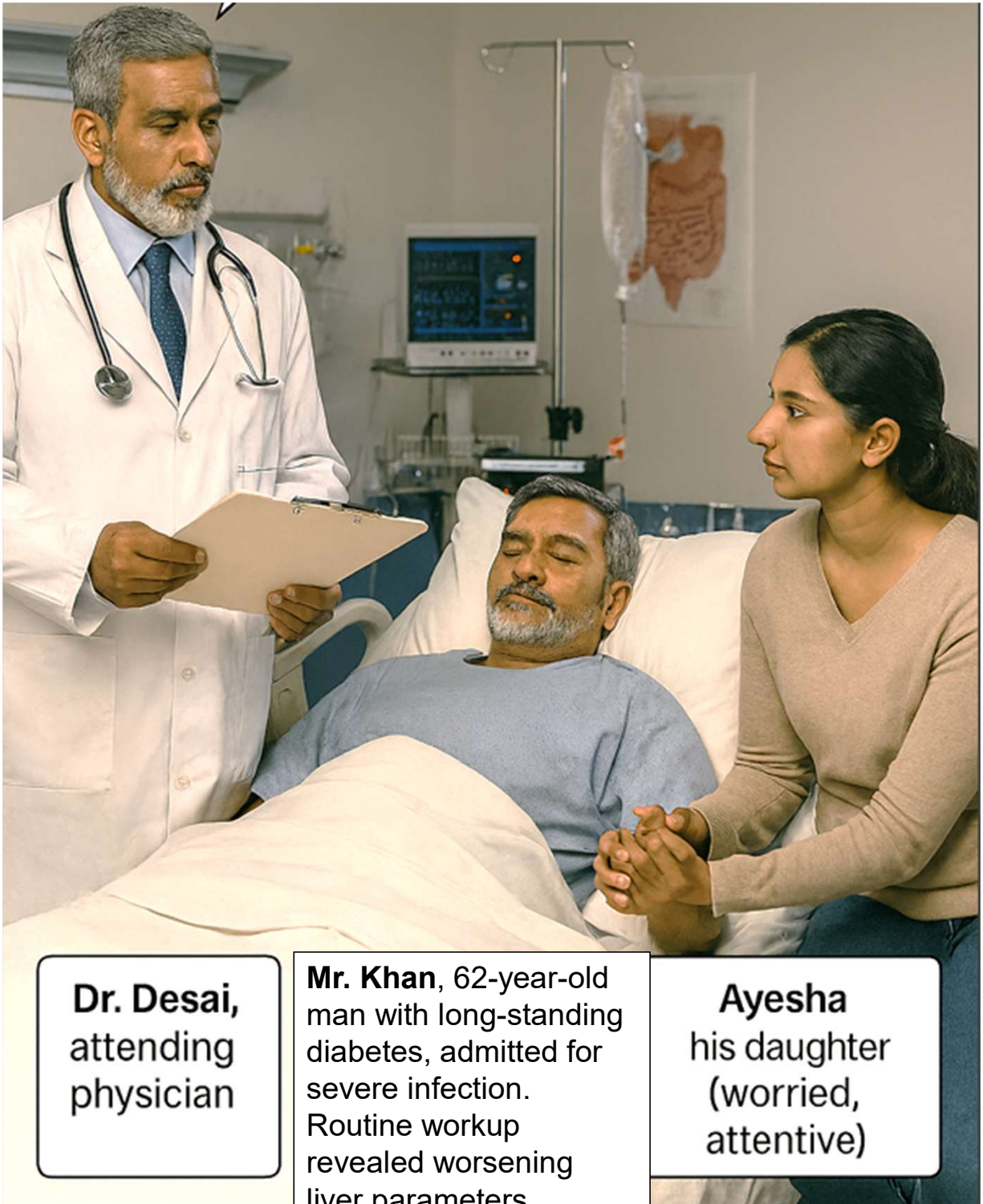


MRI-confirmed improvement in MASLD with empagliflozin



Dr. Desai,
attending
physician

Mr. Khan, 62-year-old
man with long-standing
diabetes, admitted for
severe infection.
Routine workup
revealed worsening
liver parameters

Ayesha
his daughter
(worried,
attentive)



<https://medicomindspro.com>

MRI-confirmed improvement in MASLD with empagliflozin

Ayesha, your father's infection is coming under control. But there's something else I want to discuss. Diabetes has started affecting his liver.

But his liver tests were just slightly high, right? His ultrasound last year was normal ...

Exactly. Ultrasound can miss early disease. That's why we did a liver MRI this time. And the MRI shows moderate fatty liver and early fibrosis.



MRI-confirmed improvement in MASLD with empagliflozin

